

Age: 18, Female, Asian
 Ectopy
 Three PVCs on 10 sec recording

Abnormal ECG

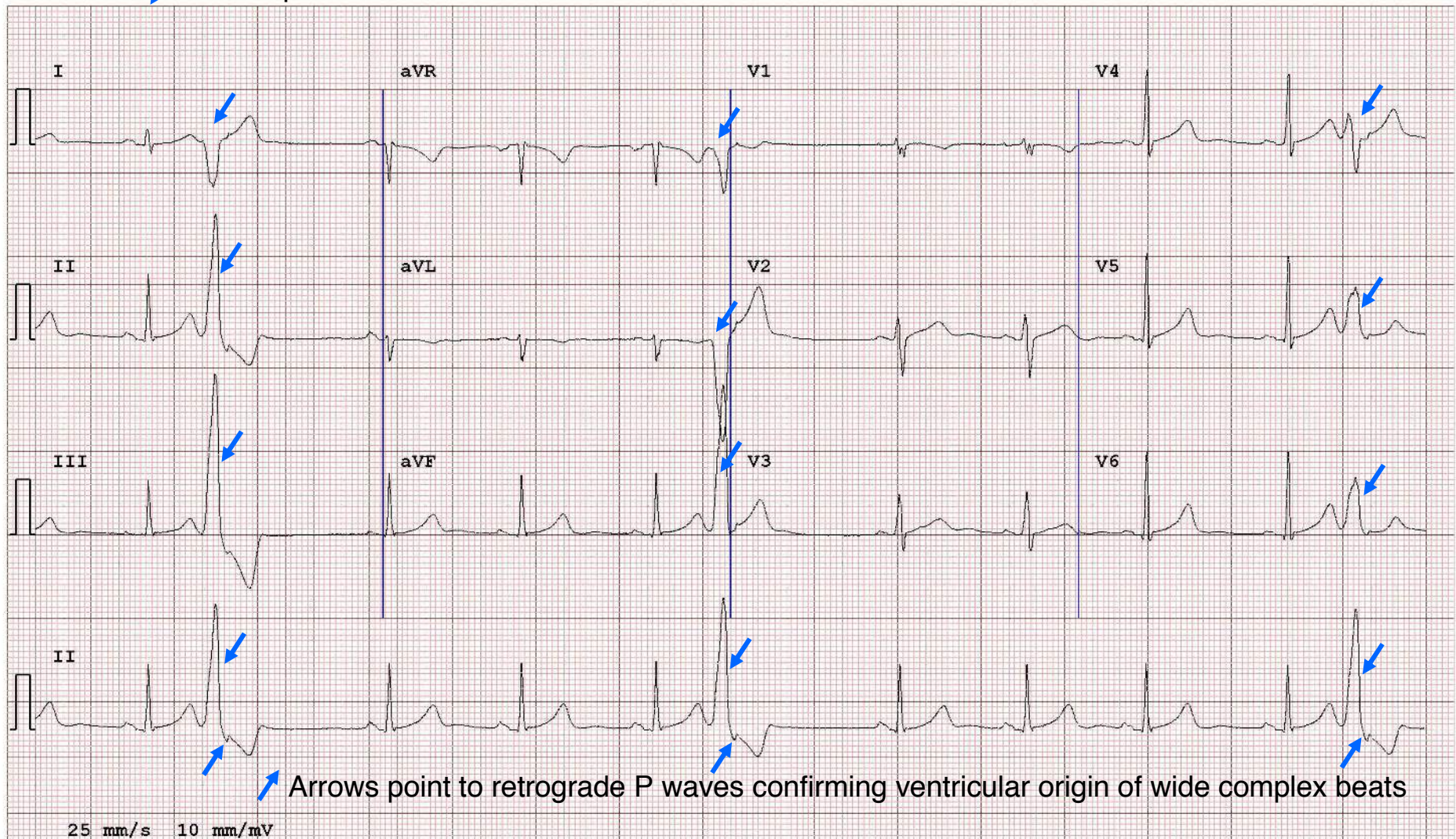
AHA: None

Reviewer: Vic Froelicher MD - 4/13/2013

Heart Rate: 66.4 bpm RR: 904 msec
 Duration (msec): P:134 QRS: 96 T:342 PR:156 QT:438 QTc:449
 P-R-T Axis(Deg): (37, 84, 65) QRS/T Spatial Angle: 63

	P Amp	Q Amp	Q Dur	R Amp	S Amp	S Dur	T Amp
V5	56	-48	18	1515	-164	29	520
aVF	71	-36	21	1083	0	0	372
V2	63	0	0	436	-675	47	296
Mag	110			1803			690

Arrows point to uni-formed PVCs



Arrows point to retrograde P waves confirming ventricular origin of wide complex beats