

Age: 18, Female, Caucasian

Normal ECG with PVCs (technical ventricular tachycardia [3 beats in a row])

Abnormal ECG

AHA: Syncope

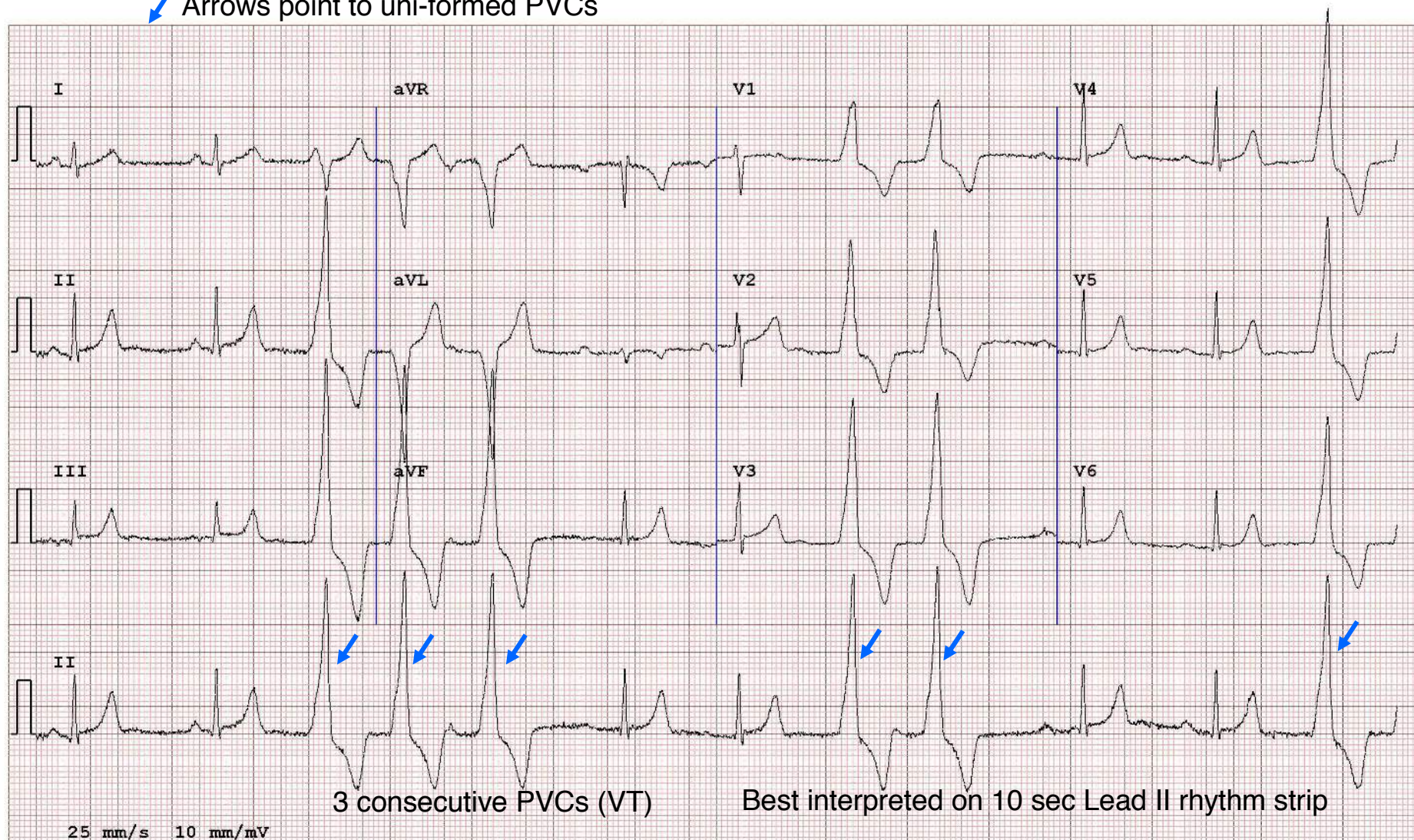
Reviewer: Vic Froelicher MD - 4/13/2013

PVCs and VT more worrisome given Hx of syncope.

Heart Rate: 73.9 bpm RR: 812 msec
Duration (msec): P: - QRS:168 T:272 PR: - QT:440 QTc:464
P-R-T Axis(Deg): (- , 97, -71) QRS/T Spatial Angle: 166

	P Amp	Q Amp	Q Dur	R Amp	S Amp	S Dur	T Amp
V5	0	0	0	2546	0	0	-860
aVF	0	0	0	3192	0	0	-1202
V2	0	0	0	2065	0	0	-675
Mag	0			4402			1623

Arrows point to uni-formed PVCs



ECG-107