

Age: 15, Female, Caucasian
ICRBBB
T-Wave Inversion: Lat

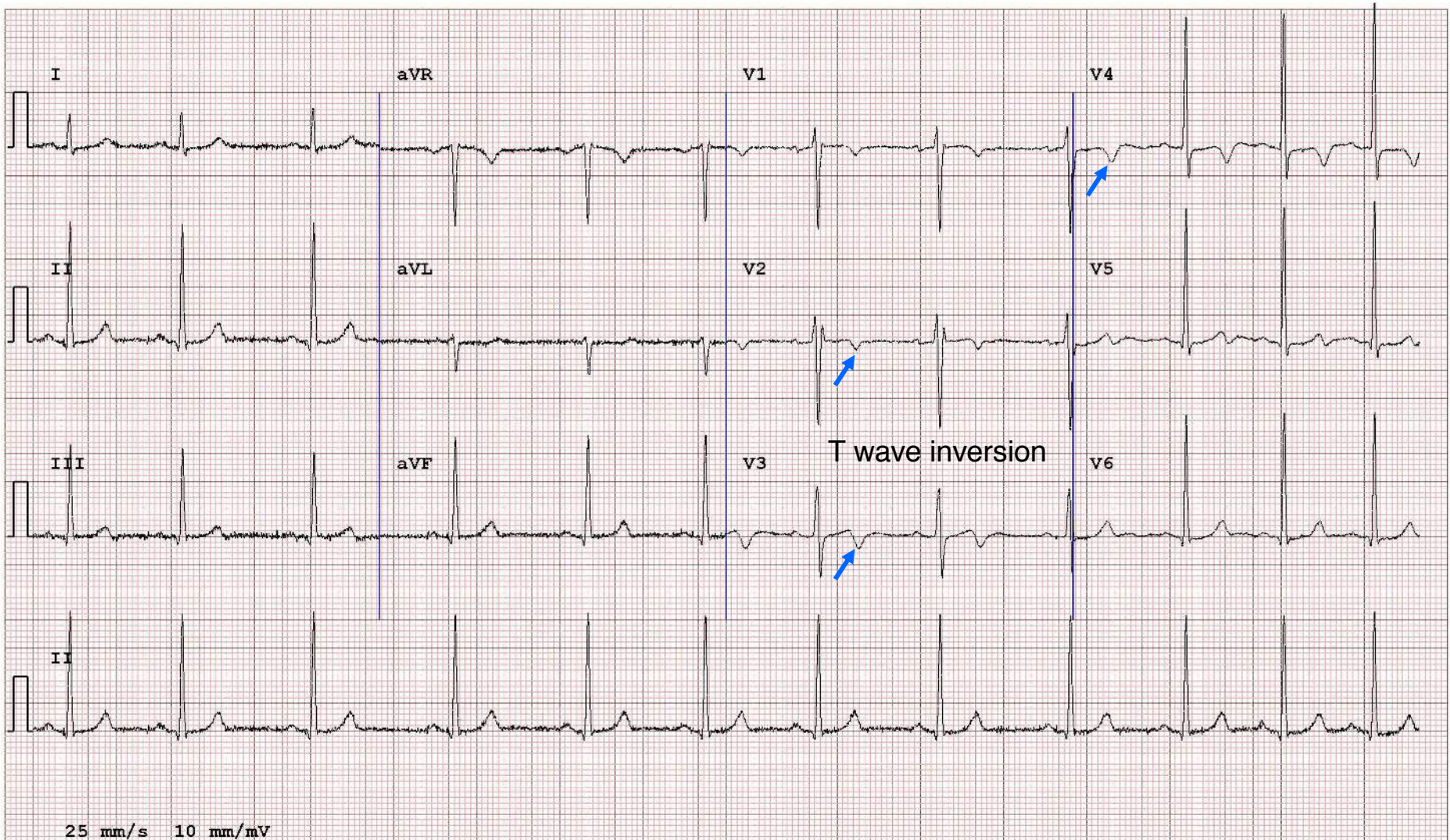
Abnormal ECG

AHA: Unknown

Reviewer: Vic Froelicher MD - 4/14/2013

Heart Rate: 71.7 bpm RR: 837 msec
Duration (msec): P:112 QRS: 90 T:294 PR:154 QT:384 QTc:404
P-R-T Axis(Deg): (52, 72, 57) QRS/T Spatial Angle: 25

	P Amp	Q Amp	Q Dur	R Amp	S Amp	S Dur	T Amp
V5	61	-92	25	2493	-250	28	144
aVF	74	-137	26	1825	-35	18	254
V2	-47	0	0	480	-1510	36	-135
Mag	95			3431			310



ECG-101