

Age: 21, Male, Afro-American  
ST Depression  
T-Wave Inversion: Lat Inf

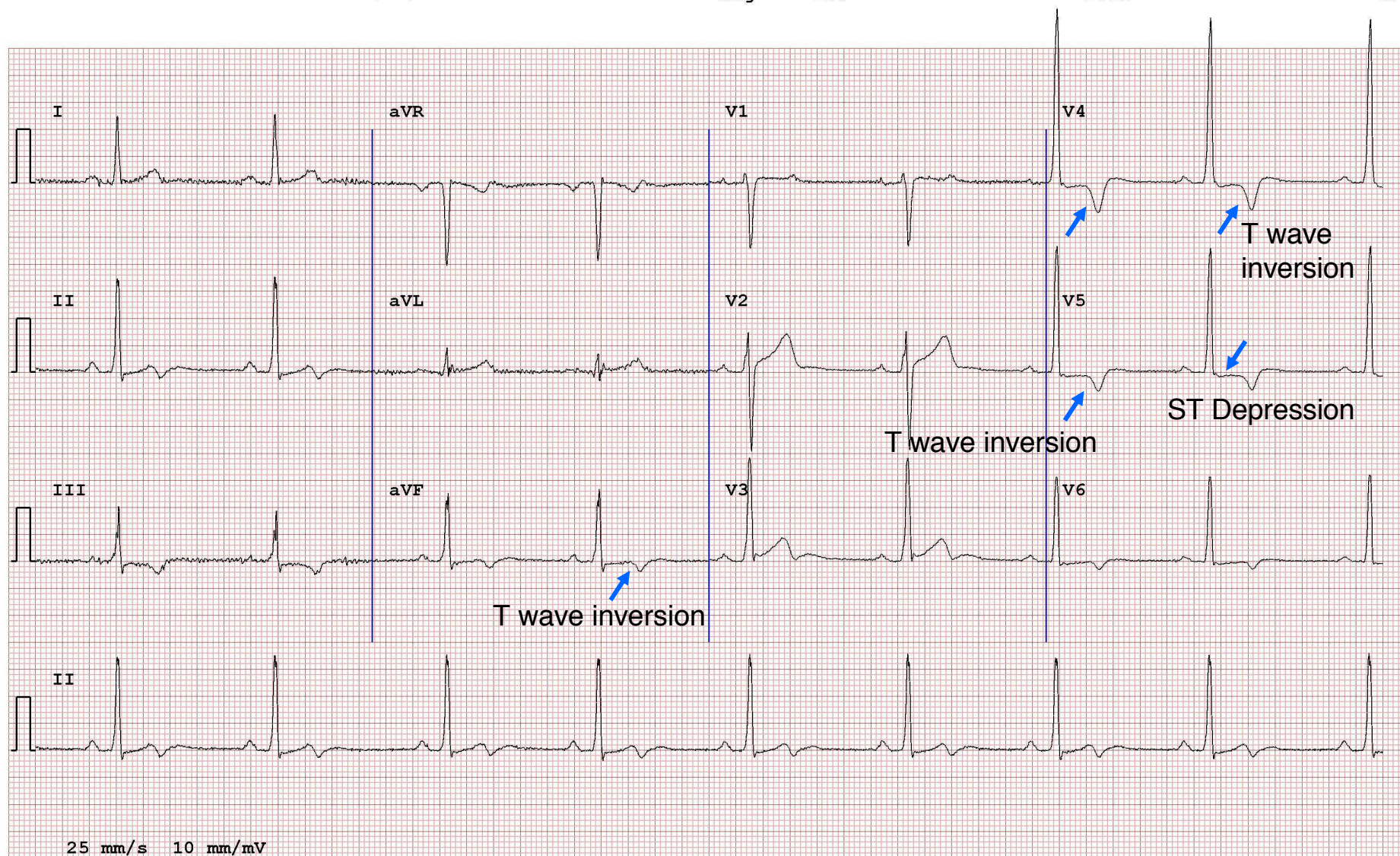
Abnormal ECG

AHA: Syncope

Reviewer: Vic Froelicher MD - 4/13/2013

Heart Rate: 52.1 bpm RR: 1152 msec  
Duration (msec): P:122 QRS:102 T:354 PR:192 QT:456 QTc:442  
P-R-T Axis(Deg): ( 43, 42, -28) QRS/T Spatial Angle: 102

	P Amp	Q Amp	Q Dur	R Amp	S Amp	S Dur	T Amp
V5	87	0	0	2300	0	0	-334
aVF	114	0	0	1295	-178	20	-156
V2	108	0	0	763	-1405	51	662
Mag	170			2925			691



ECG-111